



# Proteogenomic analysis in an early onset diffuse gastric cancer patient revealed alterations in PIK3R1, TP53, SMAD4 and a potential role of the PI3K-AKT and EGFR pathways: a case report

Miguel Cordova-Delgado<sup>1,2^</sup>, Mauricio P. Pinto<sup>1^</sup>, Gonzalo Pizarro<sup>1</sup>, Elard Koch<sup>3^</sup>, Cristian Vargas<sup>3</sup>, Mauricio Hernández<sup>3^</sup>, Guillermo Nourdin<sup>3^</sup>, Pablo Saldivia<sup>3</sup>, Maria Paz Rodriguez Z.<sup>4^</sup>, Alejandro Berkovits<sup>4</sup>, Patricio Manque<sup>4^</sup>, Juvenal A. Rios<sup>4^</sup>, Benjamin Garcia-Bloj<sup>4^</sup>, Marcelo Garrido<sup>4^</sup>

<sup>1</sup>Departamento de Hematología y Oncología, Facultad de Medicina, Pontificia Universidad Católica de Chile, Santiago, Chile; <sup>2</sup>Facultad de Química y Farmacia, Universidad de Chile, Santiago, Chile; <sup>3</sup>Instituto MELISA, Concepción, Chile; <sup>4</sup>Centro de Oncología de Precisión, Escuela de Medicina, Universidad Mayor, Santiago, Chile

Correspondence to: Marcelo Garrido, MD. Centro de Oncología de Precisión, Escuela de Medicina, Universidad Mayor, Santiago, Chile. Email: marcelo.garrido@umayor.cl.

**Background:** Early-onset gastric cancers (EOGC) are poor prognosis hard-to treat malignancies that affect young individuals (<45 years old).

**Case Description:** Herein we describe the case of a 26-year-old female EOGC patient that initially displayed stable disease after first-line CAPOX plus immunotherapy. However, patient eventually developed progressive disease and was consecutively switched to paclitaxel plus ramucirumab, and palliative irinotecan. In search for therapeutic alternatives a proteo-genomic analysis was performed in a tissue biopsy taken after the first progression. Our analyses found a total of 18 somatic mutations, including *TP53* and *PIK3R1*, and a previously unreported germline alteration in the tumor suppressor *SMAD4*. Also, our proteomic analysis found 62 proteins previously documented as “enriched in stomach cancer” and AKT/mTOR and EGFR as pathways with therapeutic potential. Unfortunately, the clinical utility of AKT/mTOR inhibitors or EGFR targeted therapies could not be assessed.

**Conclusions:** As explained above EOGC is a growing health concern that affects young individuals. Furthermore, the reported case displayed a poor response to standard therapy including checkpoint inhibitors and chemotherapy despite the presence of biomarkers that predict a favorable outcome. Future studies should adopt alternative approaches to find novel, more effective therapies.

**Keywords:** Proteogenomics; early onset gastric cancer; SMAD4; case report

Submitted Nov 17, 2021. Accepted for publication May 06, 2022.

doi: 10.21037/jgo-21-780

View this article at: <https://dx.doi.org/10.21037/jgo-21-780>

<sup>^</sup> ORCID: Miguel Cordova-Delgado, 0000-0002-3132-226X; Mauricio P. Pinto, 0000-0003-2484-8033; Elard Koch, 0000-0002-1244-3007; Mauricio Hernández, 0000-0002-2277-0132; Guillermo Nourdin, 0000-0001-8890-4896; Maria Paz Rodriguez Z., 0000-0001-8892-431X; Patricio Manque, 0000-0002-6606-0896; Juvenal A. Rios, 0000-0001-7554-8837; Benjamin Garcia-Bloj, 0000-0001-6634-025X; Marcelo Garrido, 0000-0001-8905-8986.

## Introduction

Typically, early-onset gastric cancers (EOGC) present at the age of 45 years old or younger. Although its prevalence ranges from 2.7% to 15% depending on the population being studied, it is generally accepted that 10% of gastric cancers (GCs) fall into this category. However, using the SEER database and a <60 years old cutoff, a recent study determined that >30% of GC cases in the United States were EOGC during the period 1973–2015. This study also found that EOGC was associated with the presence of signet-ring cells, diffuse histology and metastatic disease, relative to “late onset” cases (1). Intriguingly, despite its early clinical onset that would suggest a strong hereditary component, reports show that only a small proportion of cases (~10%) are associated with germinal mutations.

To date, cancer heterogeneity remains a major obstacle for the development of effective therapies. In recent decades, the development of massively-parallel sequencing techniques [such as next generation sequencing (NGS) and RNA-sequencing (RNASeq)] has allowed the identification of distinctive molecular signatures in several malignancies, including GC; thereby establishing molecular subtypes of the disease. In this regard, one of the best examples is the classification elaborated by The Cancer Genome Atlas Research Network Group (TCGA) (2). Molecular characterization studies in EOGC patients have shown high rates of *CDH1* but similar rates of *TP53* mutations (3) compared to “traditional” GC, along with a higher frequency of Epstein-Barr virus positive (EBV+) and genomically stable (GS) molecular subtypes (1). Moreover, a related study found a lower frequency of *RHOA* somatic mutations in EOGC (4). Interestingly, unlike “traditional” GC studies have also demonstrated higher mutation rates on *MUC5B* and *BANP* (5).

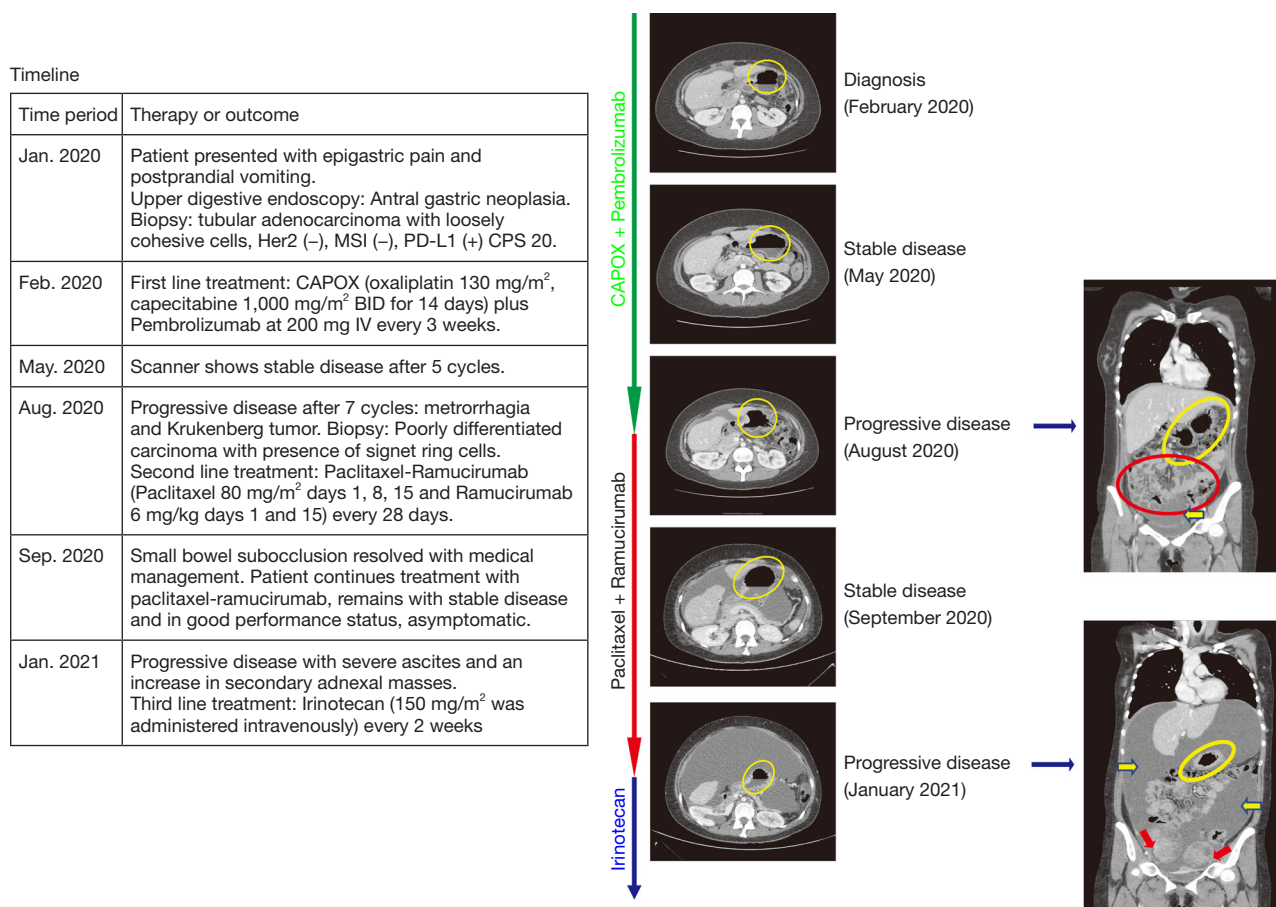
Herein, we report clinical and proteogenomic characteristics of a 26-year-old EOGC patient with a tubular poorly cohesive cell adenocarcinoma characterized by rapid clinical deterioration and unfavorable prognosis. We present the following case in accordance with the CARE reporting checklist (available at <https://jgo.amegroups.com/article/view/10.21037/jgo-21-780/rc>).

## Case presentation

The patient was a 26-year-old female with a history of insulin resistance and a laparoscopic cholecystectomy for gallstones. In January 2020 patient came to the clinic after

3-month of episodic epigastric pain and post-prandial vomiting. Upper digestive endoscopy revealed an antral gastric neoplasia. Endoscopic biopsy confirmed a tubular adenocarcinoma with poorly cohesive cells. Molecular studies demonstrated HER2 negativity, MMR proficiency and PD-L1/combined positive score (CPS) =20. Timeline of relevant therapies and clinical follow-up is summarized in *Figure 1* (left panel). Computed tomography (CT) scan showed thickening of the gastric mucosa, epigastric and infra-pyloric adenopathies and peritoneal carcinomatosis (*Figure 1*, right panels); in February 2020, patient started first-line CAPOX + pembrolizumab in the context of a clinical trial. After 5 cycles, CT scan showed stable disease. At cycle 7, the patient developed metrorrhagia and abdominal pain. In August 2020 a gynecological ultrasound discovered bilateral adnexal masses. Scanner confirmed progression of peritoneal carcinomatosis. Biopsy revealed a signet ring cell+/poorly differentiated carcinoma. The same biopsy sample was used for a proteogenomic study. Then in August 2020, patient started second-line paclitaxel plus ramucirumab for metastatic gastric cancer. A week after the patient was hospitalized for partial intestinal occlusion in the small bowel eventually resolved by systemic corticosteroids. The patient displayed good tolerance to paclitaxel plus ramucirumab and maintained performance status without symptoms until January 2021 when a follow-up CT scan showed an increase in ascites and secondary adnexal masses. Following progression, clinical trial blind information was open to decide next treatment (third line). Patient then received palliative irinotecan and remained under this treatment until April 14th, 2021, when she passed away.

As mentioned, a NGS panel of 688 cancer-related genes (Sentis Cancer + Discovery, BGI) found 18 somatic mutations in a GC biopsy (FFPE) of the patient. Three of them were clinically relevant and 15 were variants of uncertain significance (VUS). One germinal likely pathogenic mutation was found. Tumor mutational burden (TMB) was 4.3 mut/MB and classified as microsatellite stable (MSS). Relevant alterations included a *TP53* mutation, p.H233\_Y234insSIH, a 3-aminoacid insertion in the DNA binding domain of p53, classified as likely pathogenic and a p53 copy number loss (*Table 1*). Analyses also found a *PIK3R1* nonsense, likely pathogenic mutation, (p.Q110\*) and a germline previously unreported intronic mutation in the *SMAD4* gene. This alteration is caused by a 45-nucleotide insertion in the exon 7—intron 7 boundary that alters the wild type donor site, probably affecting



**Figure 1** Timeline of the case. Left panel shows a timeline of the case and relevant outcomes. Right panels show CT images at specific times, yellow circles indicate parietal thickening. Frontal images were obtained at progression (August 2020 and January 2021), yellow circles highlight the primary lesion and perigastric adenopathies. Red circle shows peritoneal carcinomatosis. Red and yellow arrows show ascites and secondary adnexal masses, respectively. CT, computed tomography.

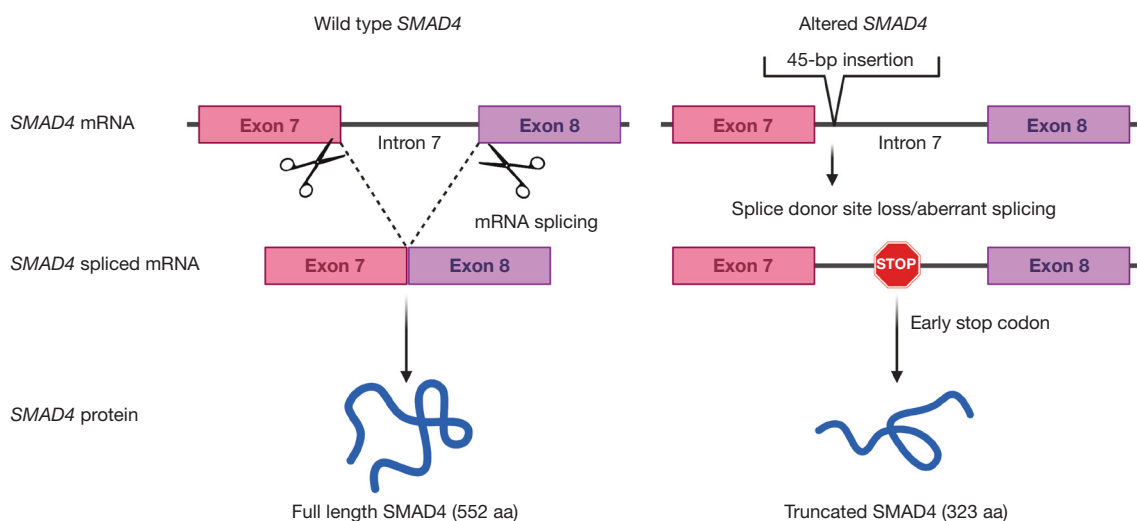
**Table 1** Clinically relevant alterations discovered by NGS analysis

Affected gene	Type of alteration	Category	Approved therapies	Functional consequence
TP53	Insertion	Somatic, likely pathogenic	None	Impaired protein and DNA binding; impaired p53 function
TP53	Copy number loss	Somatic, likely pathogenic	None	TP53 deletion and poorer survival
PIK3R1	Non-sense mutation	Somatic, likely pathogenic	None	Under-expression and poorer survival
SMAD4	Intronic insertion	Germinal, likely pathogenic	None	Aberrant mRNA splicing leads to truncated form of protein

NGS, next generation sequencing.

splicing (Figure 2). Interestingly, skipping of intron 7 and the use of alternative splicing donor sites causes an early stop codon that translates into a truncated protein of 323 amino acids, versus 552 in the full-length protein. The

truncated protein loses the MH2 domain in SMAD4, which is required for homomeric and heteromeric interactions and transcriptional regulation. Please note that our *in-silico* prediction of functional impact of this alteration should be



**Figure 2** Hypothetical impact of the germline intronic insertion in *SMAD4*. Left panel shows the normal processing of the *SMAD4* mRNA and the generation of the full length SMAD4 protein. Right panel shows that a 45-bp insertion causes aberrant splicing with an early stop codon and generates a truncated form of SMAD4 protein.

further validated.

In addition, we performed an exploratory qualitative proteomic analysis seeking to identify relevant proteins in the biology and pharmacology of this aggressive type of GC. A workflow of the proteomic analysis can be found in [Figure S1](#). Briefly, a fresh frozen biopsy from the same tumor was used for the proteomic profile characterization. A total of 7,109 proteins were identified, among these 25 have been reported as “most abundant non-silent variant genes”, 89 as “unfavorable prognosis targets”, and 91 as “known druggable proteins” (6). Also, 62 out of 147 were identified as “proteins enriched in stomach cancer” according to The Human Protein Atlas (7) ([Figure 3A](#)). Regarding potential druggable targets, we identified AKT1/mTOR and EGFR pathways; [Figure 3B](#) show oncogenic and tumor suppression proteins discovered using our approach and the signaling pathway they belong. Unfortunately, our approach did not allow us to identify under/over expressed pathways/proteins via a quantitative or specific phosphoproteomic analysis. A full list of identified proteins can be found in website (<https://cdn.amerigroups.cn/static/application/011747afd4dd140646bb20a12cac8bce/jgo-21-780-1.xlsx>).

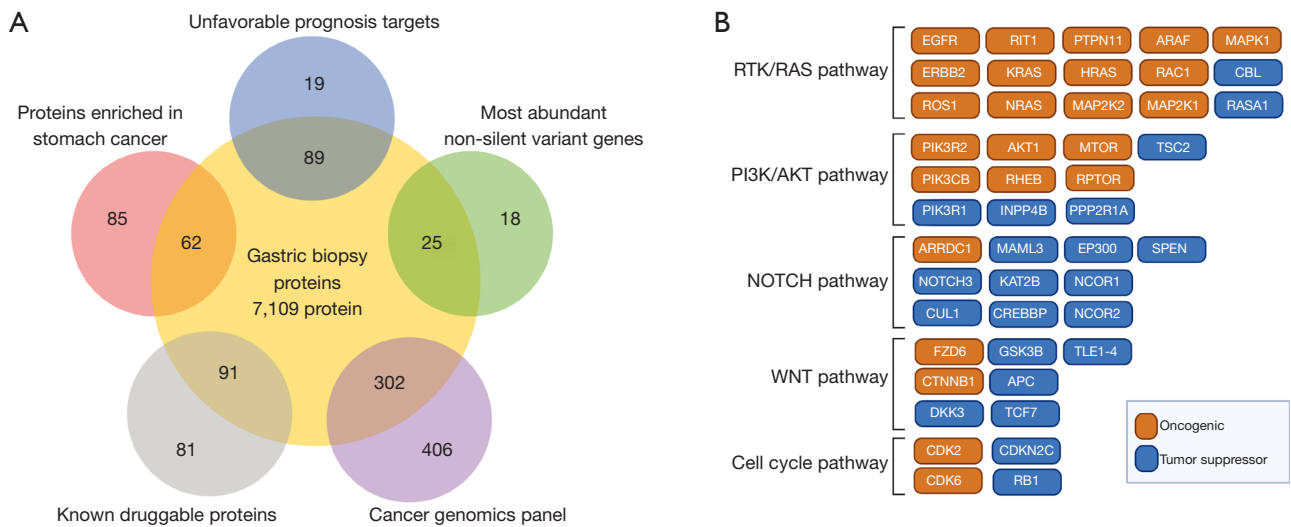
#### Ethical statement

All procedures performed in the study were in accordance with the ethical standards of the institutional and/or national research committee(s) and with the Declaration of

Helsinki (as revised in 2013). Written informed consent was obtained from the patient for publication of this case report and accompanying images. A copy of the written consent is available for review by the editorial office of this journal.

#### Discussion

Early-onset GC incidence has steadily increased over the last 4 decades (1). A recent population-based cohort study assessed global GC incidence and mortality during the 1980–2018 period and reported an increase in GC incidence among <40 years old individuals in several countries including the United Kingdom, Sweden and Ecuador (8). Studies suggest that this increase is not linked to traditional risk factors that affect GC incidence such as binge drinking or smoking (9,10). Moreover, EOGC seems to display distinct clinico-pathological characteristics versus traditional GC. Studies report a predominance of the GS subtype in EOGC, which is characterized by poor prognosis, and a lack of therapeutic benefit by traditional systemic treatments such as chemotherapy (11). Current literature indicates that EOGC is more frequent in females (12–14), generally of diffuse type (14), multifocal (15) and non-microsatellite instability (MSI) (16,17). It is also estimated that about 10% of cases have a family history (9). Accordingly, the patient on this report was a female, MSS, HER2–, and therefore did not qualify for standard targeted therapies, like trastuzumab. As occurs with “traditional” or “ordinary”



**Figure 3** Proteomic analysis. (A) Shows a comparative diagram of protein match between the patient biopsy and published datasets including “most abundant non-silent variant genes”, “unfavorable prognosis targets” and “known druggable proteins”, “proteins enriched in stomach cancer” and “cancer genomics panel”. (B) Shows oncogenic (orange) and tumor suppressor (blue) proteins detected by our proteomic analysis in the biopsy sample.

GC (18), ethnicity appears to be a significant risk factor for EOGC. A retrospective study that included >3,800 EOGC cases in Hispanic/Latino-origin US residents found that Mexican or Central/South American patients were more likely to be diagnosed with EOGC versus Cuban, Puerto Rican or Dominican Republic counterparts (19). In fact, the percentage of <40 years. Patients among Mexicans or Central/South Americans was 15% or 11%, respectively versus 3% in the entire cohort of the National Cancer Database, used as reference for this study.

Although our NGS analyses did not find relevant actionable targets, our proteomic analysis identified AKT/mTOR and EGFR as potential actionable pathways, which partially explains the rapid progression (1). Usually, EOGCs are linked to the EBV+ subtype and immunotherapy response, however this patient was categorized as EBV- and remained with stable disease for a relatively short period (5 cycles) after receiving CAPOX plus pembrolizumab. Similarly, a CPS =20 would also suggest immunotherapy response (20). Unfortunately, this was not the case. A report demonstrated a high spatial and temporal heterogeneity in PD-L1 expression in gastroesophageal adenocarcinoma (21). Thus, a potential explanation could be a rapid clonal expansion of tumor cells that became resistant to the checkpoint inhibitor.

Evidently, sporadic EOGC cases or those with a weak

family history cannot be explained by traditional genetics. Our report is a case in point. Proteomic or epigenetic analyses could offer an alternative approach to discover potential therapies. Unfortunately, given the limitations of our proteomic analysis we were unable to test the clinical efficacy of targeting the AKT/mTOR or the EGFR pathways in this patient. Notably, a previous case report demonstrates long term survival in a metastatic GC patient by the combined use of cetuximab and FOLFIRI (22). On the other hand, in line with our findings, investigators have also speculated that PIK3CA or AKT inhibitors could be a promising alternative for GC patients (23,24). Obviously, more comprehensive studies should explore other alternatives such as DNA methylation in EOGC.

In general, it is assumed that younger patients are exposed to fewer environmental carcinogens and therefore the underlying causes of EOGC are mainly genetic, however as mentioned above only 10% of cases report a family history. Interestingly, the presence of a germline *SMAD4* mutation in this patient suggests a hereditary component on EOGC. *SMAD4* (formerly called *DPC4*) is widely recognized as a tumor suppressor gene, frequently mutated in pancreatic (25) and colon (26) cancers. In mice, heterozygous null *SMAD4* mutants (*SMAD4*<sup>+/-</sup>) develop GI polyposis and tumors that overexpress Cyclin D1 and TGF- $\beta$  (27). Furthermore, concomitant loss of *CDH1* and

*SMAD4* in mice causes nuclear accumulation of  $\beta$ -catenin that promotes diffuse-type gastric adenocarcinomas and metastasis (28). In humans, a study reports 21% of juvenile polyposis syndrome (JPS) patients harbored germline *SMAD4* alterations. Unlike our study, *SMAD4* mutations were detected in exons 1, 4, 8, 10 and 11; investigators speculate that a wide range of *SMAD4* alterations can affect TGF- $\beta$  signaling (29). A similar study found a total of 17 germline *SMAD4* mutations and six large deletions in a cohort of 80 JPS patients, among these 11 were predicted to generate a truncated protein (30). Moreover, a systematic analysis identified *SMAD4* as a GC susceptibility gene (31). Besides germinal alterations, somatic *SMAD4* mutations are common among poorly cohesive gastric carcinoma patients (32). Finally, a study that analyzed 80 sporadic early onset diffuse gastric cancer patients by whole exome sequencing found a high prevalence of *CDH1*, *TP53*, *PIK3CA* and *TGFBR1* somatic mutations (4) partially confirming our findings. Interestingly, somatic *CDH1* and *TGFBR1* mutations were more frequently observed among females.

## Conclusions

In summary, EOGC are hard-to-treat, poor prognosis malignancies with an increasing incidence. Tumor mutational profiling in this refractory EOGC patient did not identify potentially actionable relevant targets. In contrast, a proteomic profiling identified signaling pathways with therapeutic potential (AKT/mTOR and EGFR). Unfortunately, given the rapid deterioration of this patient the clinical utility of this approach could not be assessed. We present a model to search for new molecular alterations or targets in refractory patients. Future studies should clarify the benefits (if any) of a combined proteogenomic approach in the treatment refractory EOGC patients.

## Acknowledgments

*Funding:* None.

## Footnote

*Reporting Checklist:* The authors have completed the CARE

reporting checklist. Available at <https://jgo.amegroups.com/article/view/10.21037/jgo-21-780/rc>

*Conflicts of Interest:* All authors have completed the ICMJE uniform disclosure form (available at <https://jgo.amegroups.com/article/view/10.21037/jgo-21-780/coif>). The authors have no conflicts of interest to declare.

*Ethical Statement:* The authors are accountable for all aspects of the work in ensuring that questions related to the accuracy or integrity of any part of the work are appropriately investigated and resolved. All procedures performed in the study were in accordance with the ethical standards of the institutional and/or national research committee(s) and with the Declaration of Helsinki (as revised in 2013). Written informed consent was obtained from the patient for publication of this case report and accompanying images. A copy of the written consent is available for review by the editorial office of this journal.

*Open Access Statement:* This is an Open Access article distributed in accordance with the Creative Commons Attribution-NonCommercial-NoDerivs 4.0 International License (CC BY-NC-ND 4.0), which permits the non-commercial replication and distribution of the article with the strict proviso that no changes or edits are made and the original work is properly cited (including links to both the formal publication through the relevant DOI and the license). See: <https://creativecommons.org/licenses/by-nc-nd/4.0/>.

## References

1. Bergquist JR, Leiting JL, Habermann EB, et al. Early-onset gastric cancer is a distinct disease with worrisome trends and oncogenic features. *Surgery* 2019;166:547-55.
2. Cancer Genome Atlas Research Network. Comprehensive molecular characterization of gastric adenocarcinoma. *Nature* 2014;513:202-9.
3. Setia N, Wang CX, Lager A, et al. Morphologic and molecular analysis of early-onset gastric cancer. *Cancer* 2020;127:103-14.
4. Cho SY, Park JW, Liu Y, et al. Sporadic Early-Onset Diffuse Gastric Cancers Have High Frequency of Somatic CDH1 Alterations, but Low Frequency of Somatic

- RHOA Mutations Compared With Late-Onset Cancers. *Gastroenterology* 2017;153:536-49.e26.
5. Mun DG, Bhin J, Kim S, et al. Proteogenomic Characterization of Human Early-Onset Gastric Cancer. *Cancer Cell* 2019;35:111-24.e10.
  6. Ge S, Xia X, Ding C, et al. A proteomic landscape of diffuse-type gastric cancer. *Nat Commun* 2018;9:1012.
  7. Uhlén M, Fagerberg L, Hallström BM, et al. Proteomics. Tissue-based map of the human proteome. *Science* 2015;347:1260419.
  8. Wong MCS, Huang J, Chan PSF, et al. Global Incidence and Mortality of Gastric Cancer, 1980-2018. *JAMA Netw Open* 2021;4:e2118457.
  9. Milne AN, Sitarz R, Carvalho R, et al. Early onset gastric cancer: on the road to unraveling gastric carcinogenesis. *Curr Mol Med* 2007;7:15-28.
  10. Ma Z, Liu X, Paul ME, et al. Comparative investigation of early-onset gastric cancer. *Oncol Lett* 2021;21:374.
  11. Sohn BH, Hwang JE, Jang HJ, et al. Clinical Significance of Four Molecular Subtypes of Gastric Cancer Identified by The Cancer Genome Atlas Project. *Clin Cancer Res* 2017;23:4441-9.
  12. Derakhshan MH, Liptrot S, Paul J, et al. Oesophageal and gastric intestinal-type adenocarcinomas show the same male predominance due to a 17 year delayed development in females. *Gut* 2009;58:16-23.
  13. Maeta M, Yamashiro H, Oka A, et al. Gastric cancer in the young, with special reference to 14 pregnancy-associated cases: analysis based on 2,325 consecutive cases of gastric cancer. *J Surg Oncol* 1995;58:191-5.
  14. Matley PJ, Dent DM, Madden MV, et al. Gastric carcinoma in young adults. *Ann Surg* 1988;208:593-96.
  15. Furukawa H, Iwanaga T, Imaoka S, et al. Multifocal gastric cancer in patients younger than 50 years of age. *Eur Surg Res* 1989;21:313-8.
  16. Lim S, Lee HS, Kim HS, et al. Alteration of E-cadherin-mediated adhesion protein is common, but microsatellite instability is uncommon in young age gastric cancers. *Histopathology* 2003;42:128-36.
  17. Carvalho R, Milne AN, van Rees BP, et al. Early-onset gastric carcinomas display molecular characteristics distinct from gastric carcinomas occurring at a later age. *J Pathol* 2004;204:75-83.
  18. Dong E, Duan L, Wu BU. Racial and Ethnic Minorities at Increased Risk for Gastric Cancer in a Regional US Population Study. *Clin Gastroenterol Hepatol* 2017;15:511-7.
  19. Karalis JD, Ju MR, Mansour JC, et al. The presentation of Hispanic gastric cancer patients varies by location of patient ancestry. *J Surg Oncol* 2021;124:1051-9.
  20. Wainberg ZA, Fuchs CS, Tabernero J, et al. Efficacy of Pembrolizumab Monotherapy for Advanced Gastric/Gastroesophageal Junction Cancer with Programmed Death Ligand 1 Combined Positive Score  $\geq 10$ . *Clin Cancer Res* 2021;27:1923-31.
  21. Zhou KI, Peterson B, Serritella A, et al. Spatial and Temporal Heterogeneity of PD-L1 Expression and Tumor Mutational Burden in Gastroesophageal Adenocarcinoma at Baseline Diagnosis and after Chemotherapy. *Clin Cancer Res* 2020;26:6453-63.
  22. Adua D, Di Fabio F, Rojas Llimpe FL, et al. Long-term survival in an advanced gastric cancer patient treated with cetuximab in association with FOLFIRI: a case report. *J Gastrointest Oncol* 2014;5:E13-17.
  23. Yang J, Nie J, Ma X, et al. Targeting PI3K in cancer: mechanisms and advances in clinical trials. *Mol Cancer* 2019;18:26.
  24. Singh SS, Yap WN, Arfuso F, et al. Targeting the PI3K/Akt signaling pathway in gastric carcinoma: A reality for personalized medicine? *World J Gastroenterol* 2015;21:12261-73.
  25. Xing S, Yang H, Liu J, et al. Prognostic Value of SMAD4 in Pancreatic Cancer: A Meta-Analysis. *Transl Oncol* 2016;9:1-7.
  26. Salovaara R, Roth S, Loukola A, et al. Frequent loss of SMAD4/DPC4 protein in colorectal cancers. *Gut* 2002;51:56-9.
  27. Xu X, Brodie SG, Yang X, et al. Haploid loss of the tumor suppressor Smad4/Dpc4 initiates gastric polyposis and cancer in mice. *Oncogene* 2000;19:1868-74.
  28. Park JW, Jang SH, Park DM, et al. Cooperativity of E-cadherin and Smad4 loss to promote diffuse-type gastric adenocarcinoma and metastasis. *Mol Cancer Res* 2014;12:1088-99.
  29. Woodford-Richens K, Bevan S, Churchman M, et al. Analysis of genetic and phenotypic heterogeneity in juvenile polyposis. *Gut* 2000;46:656-60.
  30. Aretz S, Stienen D, Uhlhaas S, et al. High proportion of large genomic deletions and a genotype phenotype update

- in 80 unrelated families with juvenile polyposis syndrome. *J Med Genet* 2007;44:702-9.
31. McKinley SK, Singh P, Yin K, et al. Disease spectrum of gastric cancer susceptibility genes. *Med Oncol* 2021;38:46.
32. Kwon CH, Kim YK, Lee S, et al. Gastric poorly cohesive carcinoma: a correlative study of mutational signatures and prognostic significance based on histopathological subtypes. *Histopathology* 2018;72:556-68.

**Cite this article as:** Cordova-Delgado M, Pinto MP, Pizarro G, Koch E, Vargas C, Hernández M, Nourdin G, Saldivia P, Rodriguez Z MP, Berkovits A, Manque P, Rios JA, Garcia-Bloj B, Garrido M. Proteogenomic analysis in an early onset diffuse gastric cancer patient revealed alterations in PIK3R1, TP53, SMAD4 and a potential role of the PI3K-AKT and EGFR pathways: a case report. *J Gastrointest Oncol* 2022;13(4):2057-2064. doi: 10.21037/jgo-21-780



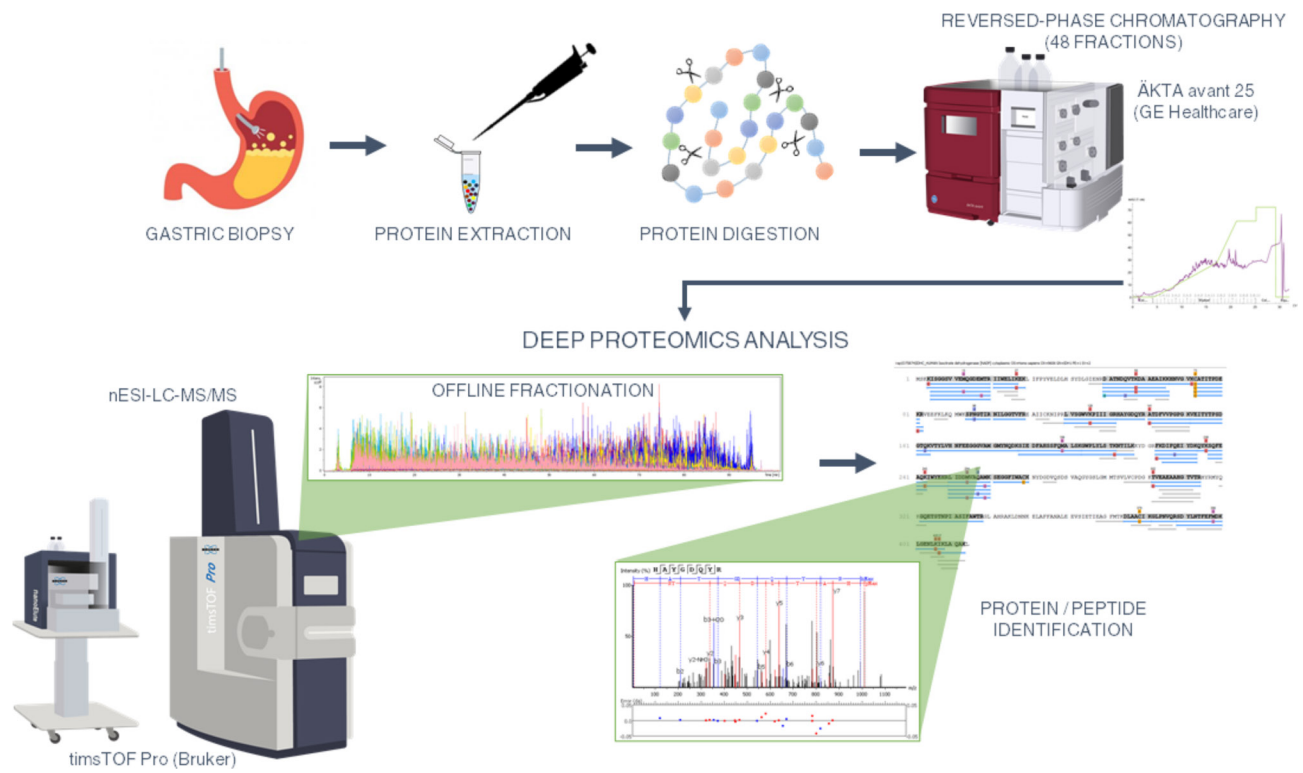


Figure S1 A workflow of the proteomic analysis.